

## Review Article

## Open Access

Antonio Mazzella, Mario Santagata, Atirge Cecere, Ettore La Mart, Alfonso Fiorelli, Gianpaolo Tartaro, Domenico Tafuri, Domenico Testa, Edoardo Grella, Fabio Perrotta, Andrea Bianco\*, Gennaro Mazzarella, Mario Santini

# Descending necrotizing mediastinitis in the elderly patients

DOI 10.1515/med-2016-0080

received August 13, 2016; accepted August 19, 2016

**Abstract:** Descending Necrotizing Mediastinitis (DNM) is a polymicrobial, dangerous and often fatal process, arising from head or neck infections and spreading along the deep fascial cervical planes, descending into the mediastinum. It can rapidly progress to sepsis and can frequently lead to death. It has a high mortality rate, up to 40% in the different series, as described in the literature. Surgical and therapeutic management has been discussed for long time especially in an elderly patient population. The literature has been reviewed in order to evaluate different pathogenesis and evolution and to recognise a correct therapeutic management.

**Keywords:** Descending necrotizing mediastinitis; Head and neck infection; Management

\*Corresponding author: **Andrea Bianco**, Department of Cardiothoracic and Respiratory Sciences, Second University of Naples/Hosp. Monaldi, Piazza Miraglia, 2, 80138 Naples, Italy, Tel.: +390815665228, Fax: +390815665230, E-mail: andrea.bianco@unina2.it

**Antonio Mazzella, Alfonso Fiorelli, Mario Santini**, Thoracic Surgery Unit, Second University of Naples, Italy

**Mario Santagata, Atirge Cecere, Ettore La Mart, Gianpaolo Tartaro**, Maxillo-Facial Surgery Unit, Second University of Naples, Italy

**Domenico Tafuri**, Department of Sport Sciences and Wellness, University of Naples "Parthenope", Naples, Italy

**Domenico Testa**, Department of Anesthesiologic, Surgical and Emergency Sciences, Otolaryngology, Head and Neck Surgery Unit, Second University of Naples, Naples, Italy

**Edoardo Grella, Fabio Perrotta, Gennaro Mazzarella**, Department of Cardiothoracic and Respiratory Sciences, Second University of Naples/Hosp. Monaldi, Italy

## 1 Introduction

Descending necrotizing mediastinitis (DNM) is a critical infection of the mediastinal connective, involving median thoracic organs. This infectious process, of usually polymicrobial origin, is caused by downward dissemination of head and neck infections, especially from the mouth or pharynx (pharyngeal, peritonsillar, dental or odontogenic abscesses) through the facial spaces [1-14]. Pearse [15] first described the disease in 1938, utilising the term DNM. Hereafter, Estrera et al. [16] established criteria for the diagnosis of DNM, which involved:

1. Clinical evidence of severe oropharyngeal infection;
2. Radiologic evidence of mediastinitis;
3. Pathological evidence of necrotizing mediastinal infection at the time of surgery or autopsy;
4. Clear association between the descending necrotizing mediastinitis and the oropharyngeal-infection.

In this context, Endo, in 1999 proposed a classification, according to localization and severity of disease [17]: I) group I (disease limited to neck and upper mediastinum, until to tracheal carena); II) group IIA (disease extended to lower anterior mediastinum, below the tracheal carena); III) group IIB (disease extended to lower anterior and posterior mediastinum, below the tracheal carena).

DNM may occur in all of ages, from childhood to seniority. In the literature, heterogeneity of people affected by DNM range between 4 and 81 years old [18-21]. DNM diagnosis is frequently delayed because DNM symptoms are also common to other thoracic diseases arising from different pathways and expressing several biomolecular markers [22-52]. To date DNM remains an aggressive and sometimes-lethal disease in despite of the evolution of antibiotic therapy, advances in innovations in diagnostic and surgical techniques [53-70], and the development of intensive care protocols. Indeed, it is characterised by a mortality rate of up to 40% [20,21,71-77], and it is linked to rapid spread of head and neck infection and diagnosis and treatment can be delayed.

The infrequency of DNM has probably been one cause in its lethality. As in other uncommon disorders, prospective investigation of these patients is extremely difficult, and the patient's reported in literature are meagre and without classed data. In the view of this aspect, no precise therapeutic schema has been proposed and the optimal treatment for DNM is still discussed. First of all, reports are in according with broad-spectrum antibiotics use at the moment of the diagnosis. Agreeing to Endo classification and severity of disease, different surgical treatments have been suggested. However, the correct surgical choice appears controversial. We have reviewed the literature, in order to discuss and clarify which could be the optimal management for these patients.

## 2 Methods

The research was made by these key words: descending necrotizing mediastinitis, odontogenic infection, head and neck infection. We have utilised Pudmed/Medline. 189 papers were founded from the above research. We have excluded no english papers, case reports and we have included series containing five or more patients. We have thus evaluated 23 papers. They are presented in Table 1.

## 3 Results

Melero Sancho *et al* [78] reported the data of 7 patients, hospitalised between 1986 and 1997, affected by DNM, due to oropharyngeal infections (57% odontogenic infections, 43% peritonsillar abscess). Every patient was treated by bilateral cervicotomy, debridement and excision of necrotic tissue and a mediastinal drainage (4 transparietal drainage, one via sternotomy, one via thoracotomy, one via mediastinotomy). The authors concluded that DNM, early diagnosed by clinical and radiological signs, required an ample cervicotomy with mediastinal drainage, generally associated with thoracotomy. This surgical approach could significantly reduce the mortality rate.

Marty-Ane<sup>´</sup> *et al* [79], reported a 10 years' experience about DNM, consisting in 12 patients. The primary oropharyngeal infection was a peritonsillar abscess in 7 patients and an odontogenic abscess in 5 patients. The treatment proposed was bilateral cervicotomy in every patients, followed by a thoracotomic debridement and drainage in 11 cases and mediastinotomy and mediastinal drainage in one case. Author finally stated that, in patients with very limited disease to the upper mediastinum, tran-

scervical mediastinal drainage alone, was justified. For all the rest of patient with clinical or radiological signs of mediastinal infections or sepsis, drainage through a major thoracic approach, was required.

Freeman *et al* [80] reported the experience of 10 patients, in whom, descending necrotizing mediastinitis was identified. After radiological diagnosis by X-ray and CT scan, 5 patients was treated by transcervical drainage procedures, 3 by transthoracic drainage procedures. Three patients required abdominal exploration and 4 underwent tracheostomy. This paper clearly shows that, computed tomographic imaging for diagnosis and following serial transcervical and transthoracic operative drainages, are recognized such as correct algorithm in treatment of DNM.

Makeieff *et al* [77], analysed pre and postoperative outcomes of 17 patients, hospitalised in a single centre. DNM was due to pharyngitis (6 cases), peritonsillar abscess (3 cases), dental abscess (6 cases), foreign body infection (1 case), and laryngitis (1 case). Mean clinical manifestations duration before diagnosis, was 6 days. Only three cases performed the cervicotomy followed by the cervical and mediastinal drainage. In 14 other cases, a thoracotomic approach, with pleural and mediastinal cavity cleaning and debridement, was performed. Authors concluded that, correct surgical choice (usually thoracotomic approach with debridement and mediastinal and pleural drainage), corroborated to correct medical management in an intensive care unit, may significantly reduce the mortality rate to less than 20%. Similar data have been reported by Papalia *et al.* [1] and Mihos *et al.* [2].

Inoue *et al* [81] showed his series of patients, affected by DNM in the period between 1996 and 2004. Peritonsillar (77%) and odontogenic (23%) abscess were the originating infectious foci. Authors classified DNM in localized (infection localized to the upper mediastinum above the level of the carina) and extensive (infection extending to the lower mediastinum beyond the level of the carina). All patients underwent to surgical mediastinal drainage. In patients affected by extended DNM, simple mediastinal drainage was corroborated by a more aggressive approach and transthoracic drainage by right VATS or right thoracotomy. Authors suggested possibility of mediastinal surgical drainage alone, in limited DNM, and necessity of thoracoscopic or thoracotomic approach in extended DNM.

Iwata *et al* [82] analysed the data of 10 patients, treated in Inohana hospital. The causes of DNM were primary peritonsillar or parapharyngeal abscess (5 patients), odontogenic abscess (3 patients), one post-tracheostomy cervical abscess. One patient rested without primary diagnosis of infection spread. In this report, for the first time,

Table 1: Review of literature

Study	Period	Pat.	Primary infection	Topographic classification	Surgical treatment	Complications	Mort. rate	Risk factors
Melero-Sancho (67) Brazil	1986-1997	7	Odontogenic (57%) Peritonsillar (43%)	/	Transcervical mediastinum drainage (4) Transcervical + transthoracic drainage via thoracotomy (2) or sternotomy (1)	Thoracic wound infection (1) Septic shock (2) Renal failure (2)	14%	Not evaluated
Mart-Ané (68) France	1989-1999	12	Odontogenic (58%) Peritonsillar (42%)	/	Transcervical mediastinum drainage (1) Transcervical+Transthoracic mediastinum drainage via thoracotomy (11)	Septic shock (1) Reintervention (2)	16,5%	Not evaluated
Freeman et al (69) USA	1980-1998	10	Odontogenic (40%) Peritonsillar (30%) Retropharyngeal (30%)	/	Transcervical mediastinum drainage (5) Transthoracic mediastinum drainage via thoracotomy (3)	ARDS (4) Renal failure (2) Cardiac failure (2) Pneumonia (2) Reintervention (5)	29%	Not evaluated
Papalia et al (1) Italy	1994-2000	13	Odontogenic (46%) Peritonsillar (38%) Post-cervical trauma (16%)	/	Transcervical mediastinum drainage (3) Transcervical+Transthoracic mediastinum drainage via toracotomy (10)	Septic shock (3) Multi-organ failure (3) Reintervention (6)	23%	Not evaluated
Mihos et al (2) Greece	1980-2001	6	Odontogenic (50%) Peritonsillar (50%)	/	Transcervical+transthoracic mediastinum drainage via thoracotomy (6)	Septic shock (1) Multi-organ failure (1)	16%	Not evaluated
Makeieff et al (66) France	1984-1998	17	Pharyngitis (35%) Peritonsillar (17%) Odontogenic (35%) Foreign body (6%) Laryngitis (6%)	/	Transcervical mediastinum drainage (3) Transcervical+transthoracic mediastinum drainage via thoracotomy (14)	Septic shock (1) Pneumonia (14) Reintervention (3)	17%	Not evaluated
Inoue et al (70) Japan	1996-2004	13	Peritonsillar (77%) Odontogenic (23%)	Group I (6) Group II (7)	Transcervical (6) Transcervical+Transthoracic mediastinal drainage via VATS (2) or thoracotomy (5)	Thoracic wound infection (1) Pyothorax requiring reintervention (1)	8%	Diabetes Immuno-compety Chronic substance abuse (nicotine, alcohol)
Iwata et al (71) Japan	1991-2003	10	Peri-pharyngeal (50%) Odontogenic (30%) Post-tracheostomy (10%) Unknown (10%)	Group I (1) Group IIA (2) Group IIB (7)	Transcervical mediastinum drainage (1) Transcervical+Transthoracic mediastinum drainage via thoracotomy (9)	Septic shock (3) Reintervention (8)	20%	Not evaluated



continued Table 1: Review of literature

Author	Year	Patients	Etiology	Group	Treatment	Complications	Mortality	Notes
Guan et al (79) China	2001-2010	15	Odontogenic (100%)	Group I (11) Group IIA (4)	Transcervical mediastinal drainage (8) Transcervical+Transthoracic drainage via thoracotomy (4) and via VATS (3)	Septic shock (1) Multi-organ failure (1) ARDS (2)	6,7%	Not evaluated
Dajer-Fadel et al (80) Mexico	1994-2007	60	Odontogenic (45%) Retropharyngeal (25%) Cervical 11,7% Other (18,3%)	/	Transcervical + Transthoracic drainage via thoracotomy (60)	Septic shock (9) Pneumonia (15) Reintervention (8) Renal failure (3) Heart failure (4)	35%	Low socio-economic status
Palma et al (81) Italy	2007-2013	32	Odontogenic (64,7%) Peritonsillar (26,5%) Tonsillitis (8,8%)	Group I (14) Group IIA (10) Group IIB (10)	Transcervical drainage (14) Transcervical+Transthoracic drainage via subxiphoid or transcutaneous (10) or via thoracotomy (10)	Septic shock (4)	11,8%	11,8%

authors based the treatment on extension-severity's classification of Endo, in order to define limited or extended DNM. Nine patients presented an extended disease, with signs of infection until to posterior lower mediastinum. Surgical treatment consisted in cervical drainage, debridement and excision of necrotic tissue in the mediastinum and pleural decortication, via thoracotomy. Post-operative antibiotics irrigation with saline were performed in all cases, until negativizing of pleural liquid culture. 8 patients were discharged without post-operative complications and the mortality rate was 20%. Authors, thus recommended this combined surgical and medical treatment, regardless of extended or limited DNM.

Misthos et al [19] evaluated 27 patients, affected by DNM and treated between 1985 and 2002. All patients presented previous cervical phlegmon. According to Endo classification [7], patients were distributed into two groups, receiving different treatment. Specifically, patients with infection involving mediastinal tissue, until tracheal carina (group I classification Endo), underwent the combined transthoracic mediastinal and cervical drainage. Patients with extended DNM (group II classification Endo) underwent the debridement of any necrotic or infectious mediastinal tissue and the wide opening of mediastinal pleura, via lateral thoracotomy (the same side as the pleural effusion). In addition, they underwent the cervical drainage, via anterior cervical incision for performing debridement and excision of necrotic neck's tissue. The authors suggestion was that early combined thoracic and cervical approach could represent the treatment of choice for DNM.

Chen et al [83] showed Taiwan's experience (18 patients) in management of DNM. Odontogenic abscess (2 cases), peritonsillar or retropharyngeal abscess (9 cases), presence of foreign bodies (3 cases) and acute epiglottitis (3 cases) represented the primary infection focus. Surgical treatment for limited disease (11 patients) consisted in anterior cervicotomy with opening, draining and debridement of necrotic neck's tissue. A subsequent mediastinal drainage was posed via mediastinoscopy, VATS or subxiphoid access. Extended disease (7 patients) was treated by debridement of the mediastinum and pleura, excision and decortication of necrotic tissue and adequate placement of silicone drains or chest tubes. Chen concluded that simple mediastinal drainage was justified, only in the limited disease. For extended disease, an additional subxiphoid approach is suggested for anterior mediastinal involvement, while video-assisted mediastinal drainage is suggested for posterior mediastinum and pleural space.

Lanisnik et al [84] analysed descending necrotizing mediastinitis following to necrotizing fasciitis of the head

and neck. In 17 of 34 original patients with necrotizing fasciitis, it was diagnosed DNM. Here too, authors adapted surgical treatment to topographic localization of infectious focus. For DNM limited to upper mediastinum, until tracheal carina, (group I) it was performed a transcervical incision with mediastinum drainage and the chest tube positioning. For the diseases extended to lower anterior mediastinum (IIA), cervical drainage was completed by a transcervical mediastinum drainage; for disease extended to lower anterior and posterior mediastinum, it was performed a lateral thoracotomy in addition to cervical and mediastinal drainage. Finally authors remarked importance of early and accurate diagnosis for a correct therapeutic choice.

Thirteen patients were included in the report of Sokouti *et al* [20]. 10 cases had Mediastinal infection derived by odontogenic abscess and 3 cases had peritonsillar and retropharyngeal abscess. 8 patients underwent cervical drainage and thoracotomy, and 5 patients were treated by cervical drainage and mediastinotomy. Here too, authors underlined the importance of an early diagnosis.

Karkas *et al* [85] reported an experience of 17 patients with DNM. In ten patients, DNM was located above the carina and could be accessed by a cervical approach. In seven patients, DNM was below the carina. Particularly, patients with an anterior involvement were treated by sternotomy; those with posterior involvement were operated via postero-lateral thoracotomy. Authors finally drafted a therapeutic algorithm for the postoperative management of DNM.

A large series of DNM patients is reported by Deu-Martin [75]. 43 patients with a clinical and radiological diagnosis of DNM, deriving from head and neck infections, were enrolled. Surgical treatment was determined according to topographic classification of Endo. Authors analysed risk factors associated to DNM. Using bivariate and multivariate analysis, it emerged that age >66 years, associate comorbidities and diagnostic period (antecedent to 2000) represented the risk factors for post-surgical death. Finally they focused on early diagnosis and on necessity of multidisciplinary treatment.

Hsu *et al* [86] compared simple transcervical drainage alone for group 1 (limited disease) to integrated treatment (cervical and thoracic) for group 2 (extended disease). No difference in terms of post operative complications or death was observed but authors concluded that an aggressive, transcervical mediastinal drainage, associated to thoracic debridement is fundamental for a good outcome.

Ridder *et al.* [21] described another large series of patients. Author analysed 45 cases of DNM and he com-

pared his results with those resulting from a meta-analysis of 26 studies. The primary infection foci were pharyngeal infection, primary neck infection, odontogenic infection, ingested foreign bodies, iatrogenic pharyngeal perforation and iatrogenic catheter infection. All patients received cervicotomy for treating original infectious focus and trans-cervical drainage of the mediastinum. In only 7 patients a transthoracic approach to drain pleural cavity was performed (5 posterolateral thoracotomy, 1 sub-xiphoid approach and 1 sternotomy). Ridder concluded affirming that the formal thoracotomy should be reserved for cases extending below the plane of the tracheal bifurcation, according to Endo classification.

Wakahara *et al* [87] reported their experience, evaluating 11 patients with DNM. In all cases, regardless to severity of disease, patients were treated by an aggressive approach: cervical drainage by cervicotomy and subsequent lateral mini-thoracotomy or thoracoscopy (if possible), with toilette, debridement and decortication of infectious and necrotic tissue. Mortality rate was 0%. Authors finally recommended this approach in management of DNM.

Kocher *et al* [88] analysed surgical therapy and outcomes in DNM “Endo type II”. All 16 patients affected by DNM, were treated by an aggressive approach, 8 via sternotomy, 8 via clamshell. In addition, authors analysed risk factors in their population and they concluded that diagnostic-therapeutic delay (>15h from beginning of symptoms) represented a very important aspect to consider in the correct management. D’Cunha *et al* [89] proposed a cervical debridement for 8 patients admitted at Minneapolis Hospital. Guan *et colleagues* [90] examined two surgical treatments for DNM, involving anterior mediastinum (cervical drainage+ trans-cervical or transthoracic mediastinum drainage versus cervical drainage + bilateral thoracoscopy via sub-xiphoid access). 15 patients were enrolled and authors concluded that in these cases treatment by trans-cervical mediastinal drainages were possible. If mediastinitis spreads to the side of the trachea, an appropriate therapy is represented by open thoracotomy. If the entire anterior mediastinum is involved (over the trachea), cleaning and debridement should be performed with a thoracoscope via the subxiphoid incision.

Dajer- Fadel *et al* [91] reported the largest series in the literature on DNM. 60 patients were enrolled in this study during a 7-years period. All the patients underwent the drainage of three mediastinum compartment (upper, lower anterior and posterior) via postero-lateral thoracotomy, in order to debride and decorticate necrotic tissue of one or both pleural cavity and mediastinum. Authors analysed risk factors for mortality and they concluded that

age and diabetes were the most important risk factors, but, not for last, the socioeconomic level.

The only prospective study included in our review is the report of Palma et al [92]. Authors prospectively examined all patients with DNM admitted to the Intensive Care Unit. 34 patients were admitted and they were treated by trans-cervical drainage in DNM type I (14 cases, 42 %); patients affected by DNM type IIA (ten cases, 29 %), was treated by the anterior mediastinum irrigation through sub-xiphoid and cervical incisions, with additional percutaneous thoracic drainage when necessary; thoracotomy with radical mediastinal surgical debridement, excision of necrotic tissue and decortication was performed for patients affected by DNM type IIB (ten cases, 29 %). In addition, they founded an important correlation ( $p=0,03$ ) between time to Intensive care unit admission after head and neck infection and pathological score (SAPS II score). Authors finally underlined the importance of an early assistance, aggressive surgery, and adequate antibiotic therapy for reducing mortality rate in DNM.

## 4 Discussion

Descending Necrotizing Mediastinitis arises from infectious process of usually polymicrobial origin, deriving and spreading from head or neck region, along the deep fascial cervical planes, descending into the mediastinum. It can rapidly progress to sepsis and frequently death.

From the analysis and review of literature, odontogenic abscess and peritonsillar abscess are the most common causes of DNM; other less frequent reported causes are parapharyngeal or retropharyngeal abscess, foreign bodies ingestion or penetration, acute epiglottitis, cervical trauma, acute pharyngitis or laryngitis, sinusitis, intravenous catheter infection and spinal corde abscess.

Clinical onset symptoms, frequently referred are: fever, cervical pain, dysphagia or odynophagia, dyspnoea and sepsis; swelling and dental pain, difficulty in opening the mouth and swallowing and jaw swelling are common in odontogenic and peritonsillar abscess. Cranial nerve deficits, linked to dissemination of necrotic and infectious tissue, may cause trismus and stridor [20].

The most frequent bacteria responsible for DNM are *beta-haemolytic Streptococcus*, *Staphylococcus aureus* and *Peptostreptococcus* for higher frequency of odontogenic or peritonsillar infections. Other frequent founded gram- bacteria are *Bacteroides*, *Pseudomonas aeruginosa*, *Enterobacter* and *Klebsiellapneumoniae*. More generally, there is not only one responsible bacterium, but a mixed

pool, consisting by both aerobic and anaerobic. Different nature of responsible microorganisms often reflected pharyngeal or odontogenic origins of this disease.

Most frequent post-operative complications, observed in the selected papers were septic shock, pleural empyema or pyothorax requiring reintervention, pneumothorax, cardiac arrhythmias, renal failure, multi-organ failure and thoracic wound infection. Mortality rate ranged between 0% [70,77,89] and 35% [91].

An attentive and careful analysis of selected papers, allowed us to investigate several points of interest.

Several surgical procedures have been proposed over years, for DNM management. However, Endo classification of 1999 [17] had represented the cornerstone in the management of this disease. Papers referring to surgical management of DNM, previous to this classification, proposed an aggressive approach consisting in mediastinum drainage and debridement of necrotic tissue, through thoracotomy, sternotomy or mediastinoscopy, but no specific surgical algorithm or rule has been recommended for these patients.

Endo et al. [17], for the first time described his classification, focusing on different topographic zones involved by infection; for every group, he proposed a different treatment, in according with gravity of disease. He established tracheal carena as topographic limit; particularly, classification provided for three different groups of patients, according to which, a different surgical approach put in place. Group I, consisted in cases with an upper mediastinum (until tracheal carena) involvement; in these circumstances, the simple radical cervicotomy with transcervical mediastinal drainage was justified. Group IIA consisted in the cases with a lower anterior mediastinal (beyond tracheal carena) involvement; suggested treatment in these situations was the radical cervicotomy and anterior mediastinal drainage through a subxiphoidal incision, or sternotomy. Sternotomy guarantees fast and simple access to the anterior mediastinum and both thoracic cavities. This approach allows one-stage procedure, avoiding patient repositioning (especially after prior cervicotomy).

However it allows limited access to the postero-basal mediastinum, especially on the left side. Group IIB, finally consisted in the cases with a lower posterior mediastinum involvement; in these cases radical cervicotomy had to be corroborated by posterior mediastinal drainage through right thoracotomy, and even through a contralateral thoracotomy in order to clean and drain all posterior mediastinum. Other reports [83,93,94] describe VATS as alternative technique. However, systematic debridement and opening (often necessary) of contralateral pleura and involved fascial spaces, which are indispensable to stop

infection and to prevent progressivity of the disease, are impossible, using VATS technique.

A conservative approach (cervicotomy and trans-cervical drainage) is justified only in DNM involving upper mediastinum (group I). In other cases, a radical and aggressive surgical treatment, consisting by right or left thoracotomy (group IIB), sternotomy or clamshell approach (group IIA and IIB), in order to debride and wash bilateral pleural cavities and mediastinum is recommended. Early identification of infectious involvement is fundamental, in order to avoid a diagnostic delay that seems to be a significant predictor of morbidity and mortality. In elderly, immune-deficiency and co-morbidities are major risk factor.

In particular, diabetes [95,96] and chronic substance abuse (eg, alcohol and/or nicotine abuse) [97] represents predisposing factors for developing DNM. Underestimation of the extent of disease and the influence of low socio-economic status may cause a delayed diagnosis or an insufficient therapy; represent other risk factors for promoting of infection's dissemination (Table 2).

The importance of a multidisciplinary approach should be considered in the DNM management. A close cooperation between anaesthesiologists, thoracic surgeons, pulmonologist, otolaryngologists and radiologists is required in order to assure the best assistance to patient. For all suspicions of DNM, an early and appropriate support or resuscitative therapy must be initiated. Intravenous broad-spectrum antibiotics (third-generation cephalosporin and metronidazole and/or clindamy-

cin or more generally penicillin and metronidazole) and airway management, represents the first step of treatment. An early antibiotic therapy, empirically begun on admission and later changed according to the microbiological examinations and antibiogram, is essential. Surgical clean up of the primitive infectious focus and the drainage and debridement of the neck and the mediastinum represents the second step in DNM management. Postoperative care plays a central role [6]. An appropriate and careful assistance by Intensive Care Unit is fundamental for these patients, in order to manage severe sepsis and/or septic shock and every possible complications, both at the beginning and after surgery [98].

A rapid CT scan control, corroborated by clinical and laboratoristic data, represents the cornerstone in the correct management of these patients. CT scan is the single most important tool for the early diagnosis of DNM and subsequent surgical drainage procedure but it is fundamental in the follow-up too; it can be helpful to evaluate the adequacy of surgical treatment or drainage, and to identify recurrent abscesses and progression of DNM, that required a quick return to operating room. Early, attentive and multidisciplinary approach can make a difference in the patient management.

## 5 Conclusions

Descending necrotizing mediastinitis (DNM) is a critical infection of the mediastinal connective and it is a life threatening condition. A close cooperation between radiologists, intensivists, pulmonologists, oral and maxillo-facial surgeons and thoracic surgeons is required to best manage these patients. Early diagnosis, use of CT scanning to monitor the disease evolution, adequate supportive care in ICU and correct surgical treatment represent the crucial points for an appropriate management. However, DNM rests to be a dangerous, destructive and fatal disease, requiring the most attentive and careful assistance by therapists.

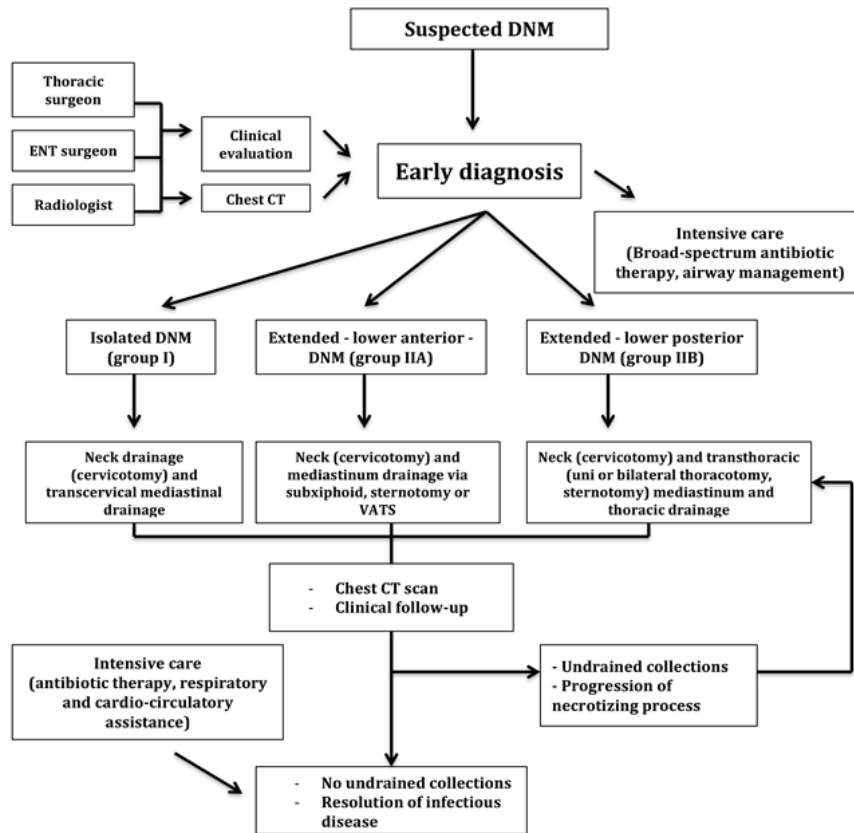
**Conflict of Interests.** The authors declare that they have no conflict of interests.

**Table 2:** Risk factors

Principal risk factors, associate to higher mortality rate
Delayed diagnosis
Immuno-competency
Co-morbidities (Diabetes)
Chronic substance abuse (alcohol, drugs)
Nicotine abuse
Low socio-economic status



Figure 1: Algorithm of review



## References

- [1] Papalia E, Rena O, Oliaro A, Cavallo A, Giobbe R, Casadio C, Maggi G, Mancuso M. Descending necrotizing mediastinitis: surgical management. *Eur J Cardiothorac Surg* 2001; 20:739-742
- [2] Mihos P, Potaris K, Gakidis I, Papadakis D, Rallis G. Management of descending necrotizing mediastinitis. *J Oral Maxillofac Surg* 2004; 62:966-972
- [3] Singhal P, Kejriwal N, Lin Z, Tsutsui R, Ullal R. Optimal surgical management of descending necrotizing mediastinitis: our experience and review of literature. *Heart Lung Circ* 2008; 17:124-128
- [4] De Freitas RP, Fahy CP, Brooker DS, Primrose WJ, McManus KG, McGuigan JA, Hughes SJ. Descending necrotizing mediastinitis: a safe treatment algorithm. *Eur Arch Otorhinolaryngol* 2007; 264: 181-187
- [5] Zabaleta J, Aguinagalde B, Izquierdo JM, Hernández CJ. Acute mediastinitis as a complication of H1N1 influenza. *Arch Bronconeumol*. 2010 Jul;46 (7):398
- [6] Geerts JW, van Driel EM, Janssen MJ. Descending mediastinitis in Epstein-Barr virus infection. *J Clin Microbiol*. 2015 May;53 (5):1781-1782
- [7] Whiteman SC, Bianco A, Knight RA, et al. Human rhinovirus selectively modulates membranous and soluble forms of its intercellular adhesion molecule-1 (ICAM-1) receptor to promote epithelial cell infectivity. *J Biol Chem* 2003;278:11954-1195461
- [8] Bianco A, Whiteman SC, Sethi SK, et al. Expression of intercellular adhesion molecule-1 (ICAM-1) in nasal epithelial cells of atopic subjects: a mechanism for increased rhinovirus infection? *Clin Exp Immunol* 2000;121:339-345
- [9] Micillo E, Bianco A, D'Auria D, et al. Respiratory infections and asthma. *Allergy* 2000;55:42-45
- [10] Sethi SK, Bianco A, Allen JT, et al. Interferon-gamma (IFN $\gamma$ ) down-regulates the rhinovirus-induced expression of intercellular adhesion molecule-1 (ICAM-1) on human airway epithelial cells. *Clin Exp Immunol* 1997;110:362-369
- [11] Bianco A, Sethi SK, Allen JT, et al. Th2 cytokines exert a dominant influence on epithelial cell expression of the major group human rhinovirus receptor, ICAM-1. *Eur Respir J* 1998;12:619-626
- [12] Bianco A, Parrella R, Esposito V, et al. Severe A (H1N1) associated pneumonia sequential to Chlamydia pneumoniae infection in healthy subject. *In Vivo* 2011;25:825-828
- [13] Giannattasio A, Brunese L, Ripabelli G, Mazarrella G, Bianco A. Coinfections with influenza virus and atypical bacteria: Implications for severe outcomes? *Clin Respir J*. 2016 Jun 1. doi: 10.1111/crj.12510
- [14] Charbonneau H, Maillet JM, Faron M et al. Mediastinitis due to Gram-negative bacteria is associated with increased mortality. *Clin Microbiol Infect*. 2014 Mar;20 (3):O197-202

- [15] Pearse HE Jr. Mediastinitis following cervical suppuration. *Ann Surg* 1938; 107:588-611
- [16] Estrera AS, Landay MJ, Grisham JM, Sinn DP, Platt MR. Descending necrotizing mediastinitis. *Surg Gynecol Obstet* 1983; 157:545-552
- [17] Endo S, Murayama F, Hasegawa T, Yamamoto S, Yamaguchi T, Sohara Y, Fuse K, Miyata M, Nishino H. Guideline of surgical management based on diffusion of descending necrotizing mediastinitis. *Jpn J Thorac Cardiovasc Surg* 1999; 47:14-19
- [18] Rocca F, Pecorari GC, Oliaro A, Passet E, Rossi P, Nadalin J, Garzino-Demo P, Berrone S. Ten years of descending necrotizing mediastinitis: management of 23 cases. *J Oral Maxillofac Surg* 2007; 65:1716-1724
- [19] Misthos P, Katsaragakis S, Kakaris S, Theodorou D, Skottis I. Descending necrotizing anterior mediastinitis: analysis of survival and surgical treatment modalities. *J Oral Maxillofac Surg* 2007; 65:635-639
- [20] Sokouti M, Nezafati S. Descending necrotizing mediastinitis of oropharyngeal infections. *J Dent Res Dent Clin Dent Prospects* 2009; 3:82-85
- [21] Ridder GJ, Maier W, Kinzer S, Teszler CB, Boedeker CC, Pfeiffer J. Descending necrotizing mediastinitis: contemporary trends in etiology, diagnosis, management, and outcome. *Ann Surg* 2010, 251:528-534
- [22] Longobardi L, Di Giorgio A, Perrotta F et al. Bronchial asthma in the elderly patient.. *J Gerontology and Geriatrics*. 2016; 64: 55-65
- [23] Corbi G, Bianco A, Turchiarelli V, Cellurale M, Fatica F, Daniele A, Mazzarella G, Ferrara N. Potential mechanisms linking atherosclerosis and increased cardiovascular risk in COPD: focus on Sirtuins. *Int J Mol Sci*. 2013 Jun 17;14 (6):12696-12713
- [24] Bianco A, Mazzarella G, Bresciani M, Paciocco G, Spiteri MA. Virus-induced asthma. *Monaldi Arch Chest Dis* 2002;57:188-190
- [25] De Simone G, Aquino G, Di Gioia C, Mazzarella G, Bianco A, Calcagno G. Efficacy of aerobic physical retraining in a case of combined pulmonary fibrosis and emphysema syndrome: a case report. *J Med Case Rep*. 2015 Apr 19;9:85
- [26] Mazzarella G, Iadevaia C, Guerra G, Rocca A, Corcione N, Rossi G, Amore D, Brunese L, Bianco A. Intralobar pulmonary sequestration in an adult female patient mimicking asthma: a case report. *Int J Surg*. 2014;12 Suppl 2:S73-77
- [27] Mazzarella G, Lucariello A, Bianco A, Calabrese C, Thanassoulas T, Savarese L, Fiumarella A, Esposito V, De Luca A. Exposure to submicron particles (PM1.0) from diesel exhaust and pollen allergens of human lung epithelial cells induces morphological changes of mitochondria tonofilaments and rough endoplasmic reticulum. *In Vivo*. 2014 Jul-Aug;28 (4):557-561
- [28] Comella P, Frasci G, De Cataldis G, et al. Cisplatin/ carboplatin+etoposide+ vinorelbine in advanced nonsmall-cell lung cancer: a multicenter randomised trial. *Gruppo Oncologico Campano Br J Cancer* 1996;74:1805-1811
- [29] Comella P, Frasci G, Panza N, et al. Cisplatin, gemcitabine, and vinorelbine combination therapy in advanced non-small-cell lung cancer: a phase II randomized study of the southern Italy Cooperative oncology group. *J Clinical Oncol* 1999;17:1526-34. 55
- [30] Frasci G, Lorusso V, Panza N, et al. Gemcitabine plus vinorelbine yields better survival outcome than vinorelbine alone in elderly patients with advanced non-small cell lung cancer. A Southern Italy Cooperative Oncology Group (SICOG) phase III trial. *Lung Cancer* 2001;34 (Suppl 4):S65-69
- [31] Piantadosi FV, Caputo F, Mazzarella G, et al. Gemcitabine, ifosfamide and paclitaxel in advanced/metastatic nonsmall cell lung cancer patients: a phase II study. *Cancer Chemother-Pharmacol* 2008;61:803-807
- [32] Cattaneo F, Guerra G, Parisi M, Lucariello A, De Luca A, De Rosa N, Mazzarella G, Bianco A, Ammendola R. Expression of Formyl-peptide Receptors in Human Lung Carcinoma. *Anticancer Res*. 2015 May;35 (5):2769-2774
- [33] A. Vatrella, S. Montagnani, C. Calabrese, R. Parrella, G. Pelaia, G.L Biscione, N. Corcione, S.A. Marsico and Guerra G. Neuropeptide expression in the airways of COPD patients and smokers with normal lung function. *J Biol Reg Homeos Ag* 2010 Oct-Dec;24 (4):425-432
- [34] Cattaneo F, Iaccio A, Guerra G, Montagnani S, Ammendola R. NADPH-oxidase-dependent reactive oxygen species mediate EGFR transactivation by FPRL1 in WKYMVm-stimulated human lung cancer cells. *Free Radic Biol Med*. 2011 Sep 15;51 (6):1126-1136
- [35] Dragoni S, Laforenza U, Bonetti E, Reforgiato M, Poletto V, Lodola F, Bottino C, Guido D, Rappa A, Pareek S, Tomasello M, Guarrera MR, Cinelli MP, Aronica A, Guerra G, Barosi G, Tanzi F, Rosti V, Moccia F. Enhanced Expression of Stim, Orai, and TRPC Transcripts and Proteins in Endothelial Progenitor Cells Isolated from Patients with Primary Myelofibrosis. *PLoS One* 2014 Mar 6;9 (3):e91099
- [36] Dragoni S, Turin I, Laforenza U, Potenza DM, Bottino C, Glasnov TN, Prestia M, Ferulli F, Saitta A, Mosca A, Guerra G, Rosti V, Luinetti O, Ganini C, Porta C, Pedrazzoli P, Tanzi F, Montagna D, Moccia F. Store-operated Ca<sup>2+</sup> entry does not control proliferation in primary cultures of human metastatic renal cellular carcinoma. *Biomed Res Int*. 2014;2014:739494
- [37] Cattaneo F, Guerra G, Parisi M, De Marinis M, Tafuri D, Cinelli M, Ammendola R. Cell-Surface Receptors Transactivation Mediated by G Protein-Coupled Receptors. *Int J Mol Sci*. 2014 Oct 29;15 (11):19700-19728
- [38] Moccia F, Zuccolo E, Poletto V, Cinelli M, Bonetti E, Guerra G, Rosti V. Endothelial progenitor cells support tumour growth and metastatisation: implications for the resistance to anti-angiogenic therapy. *Tumour Biol*. 2015 Aug;36 (9):6603-6614
- [39] Dragoni S, Reforgiato M, Zuccolo E, Poletto V, Lodola F, Ruffinatti FA, Bonetti E, Guerra G, Barosi G, Rosti V, Moccia F. Dysregulation of VEGF-induced pro-angiogenic Ca<sup>2+</sup> oscillations in primary myelofibrosis-derived endothelial colony forming cells. *Exp Hematol*. 2015 Dec;43 (12):1019-1030. e3
- [40] Zuccolo E, Bottino C, Diofano F, Poletto V, Codazzi AC, Mannarino S, Campanelli R, Fois G, Marseglia GL, Guerra G, Montagna D, Laforenza U, Rosti V, Massa M, Moccia F. Constitutive store-operated Ca<sup>2+</sup> entry leads to enhanced nitric oxide production and proliferation in infantile hemangioma-derived endothelial colony forming cells. *Stem Cells Dev*. 2016 Feb 15;25 (4):301-319
- [41] Poletto V, Dragoni S, Lim D, Biggiogera M, Aronica A, Cinelli M, De Luca A, Rosti V, Porta C, Guerra G, Moccia F. Endoplasmic Reticulum Ca<sup>2+</sup> Handling and Apoptotic Resistance in Tumor-Derived Endothelial Colony Forming Cells. *J Cell Biochem*. 2016 Oct;117 (10):2260-71. doi: 10.1002/jcb.25524

- [42] Moccia F, Zuccolo E, Poletto V, Turin I, Guerra G, Pedrazzoli P, Rosti V, Porta C, Montagna D. Targeting Stim and Orai proteins as an alternative approach in anticancer therapy. *Curr Med Chem*. 2016 Jun 7. [Epub ahead of print]
- [43] Berra-Romani R, Avelino-Cruz JE, Raqeeb A, Della Corte A, Cinelli M, Montagnani S, Guerra G, Moccia F, Tanzi F. Ca<sup>2+</sup>-dependent nitric oxide release in the injured endothelium of excised rat aorta: a promising mechanism applying in vascular prosthetic devices in aging patients. *BMC Surg* 2013 Oct 8;13 (Suppl 2):S40
- [44] Moccia F, Dragoni S, Cinelli M, Montagnani S, Amato B, Rosti V, Guerra G, Tanzi F. How to utilize Ca<sup>2+</sup> signals to rejuvenate the reparative phenotype of senescent endothelial progenitor cells in elderly patients affected by cardiovascular diseases: a useful therapeutic support of surgical approach? *BMC Surg* 2013 Oct 8;13 (Suppl 2):S46
- [45] Dragoni S, Guerra G, Pla Af, Bertoni G, Rappa A, Poletto V, Bottino C, Aronica A, Lodola F, Cinelli Mp, Laforenza U, Rosti V, Tanzi F, Munaron L, Moccia F. A Functional Transient Receptor Potential Vanilloid 4 (Trpv4) Channel Is Expressed In Human Endothelial Progenitor Cells. *J Cell Physiol* 2015 Jan;230 (1):95-104
- [46] Corbi G, Bianco A, Turchiarelli V, Cellurale M, Fatica F, Daniele A, Mazzarella G, Ferrara N. Potential Mechanisms Linking Atherosclerosis and Increased Cardiovascular Risk in COPD: Focus On Sirtuins. *Int J Mol Sci*. 2013 Jun17;14 (6):12696-12713
- [47] Nigro E, Scudiero O, Sarnataro D, Mazzarella G, Sofia M, Bianco A, Daniele A. Adiponectin affects lung epithelial A549 cell viability counteracting TNF $\alpha$  and IL-1 $\beta$  toxicity through AdipoR1. *Int J Biochem Cell Biol*. 2013 Jun;45 (6):1145-1153
- [48] Nigro E, Daniele A, Scudiero O, Ludovica Monaco M, Roviezzo F, D'Agostino B, Mazzarella G, Bianco A. Adiponectin in asthma: implications for phenotyping. *Curr Protein Pept Sci*. 2015;16 (3):182-187
- [49] Bianco, A.; Mazzarella, G.; Turchiarelli, V.; Nigro, E.; Corbi, G.; Scudiero, O.; Sofia, M.; Daniele, A. Adiponectin: an attractive marker for metabolic disorders in Chronic Obstructive Pulmonary Disease (COPD). *Nutrients*, 2013, 15 (10), 4115-4125
- [50] Daniele A, De Rosa A, Nigro E, Scudiero O, Capasso M, Masullo M, de Laurentiis G, Oriani G, Sofia M, Bianco A. Adiponectin oligomerization state and adiponectin receptors airway expression in chronic obstructive pulmonary disease. *Int J Biochem Cell Biol*. 2012 Mar;44 (3):563-569
- [51] Nigro E, Scudiero O, Monaco ML, Palmieri A, Mazzarella G, Costagliola C, Bianco A, Daniele A. New insight into adiponectin role in obesity and obesity-related diseases. *Biomed Res Int*. 2014; 2014:658913
- [52] Nigro E, Imperlini E, Scudiero O, Monaco ML, Polito R, Mazzarella G, Orrù S, Bianco A, Daniele A. *Respir Res*. 2015 Jun 24;16:74. doi: 10.1186/s12931
- [53] Santini M, Fiorello A, Cappabianca S, Vicidomini G. Unusual case of Boerhaave syndrome, diagnosed late and successfully treated by Abbott's T-tube. *J Thorac Cardiovasc Surg*. 2007 Aug;134 (2):539-40
- [54] Santini M, Fiorello A, Vicidomini G, Busiello L, Baldi A. A surgical case of pyothorax-associated lymphoma of T-cell origin arising from the chest wall in chronic empyema. *Ann Thorac Surg*. 2009 Aug;88 (2):642-645
- [55] Santini M, Fiorello A, Di Crescenzo VG, Vicidomini G, Busiello L, Laperuta P. Use of unidirectional endobronchial valves for the treatment of giant emphysematous bulla. *J Thorac Cardiovasc Surg*. 2010 Jan;139 (1):224-226
- [56] Brunese L, Greco B, Setola FR, Lassandro F, Guarracino MR, De Rimini M, Piccolo S, De Rosa N, Muto R, Bianco A, Muto P, Grassi R, Rotondo A. Non-small cell lung cancer evaluated with quantitative contrast-enhanced CT and PET-CT: net enhancement and standardized uptake values are related to tumour size and histology. *Med Sci Monit*. 2013 Feb7;19:95-101
- [57] Izzo A, Perrotta F, Cennamo A, Cerqua FS, Rinaldi L, Mazzella A, Grella E, Tranfa C, Bianco A, Stefanelli F, Mazzarella G. Spirometry in elderly laryngectomized patients: a feasibility study. *Int J Surgery* 2016 May 30. pii: S1743-9191 (16)30144-3
- [58] Maniscalco M, Bianco A, Mazzarella G, Motta A. Recent Advances on Nitric Oxide in the Upper Airways. *Curr Med Chem*. 2016 Jun 27. [Epub ahead of print]
- [59] Maniscalco M, Vitale C, Vatrella A, Molino A, Bianco A, Mazzarella G. Fractional exhaled nitric oxide-measuring devices: technology update. *Med Devices (Auckl)*. 2016 Jun 23;9:151-160
- [60] de Laurentiis G, Paris D, Melck D, Montuschi P, Maniscalco M, Bianco A, Sofia M, Motta A. Separating Smoking-Related Diseases Using NMR-Based Metabolomics of Exhaled Breath Condensate. *J Proteome Res*. 2013 Mar 1;12 (3):1502-1511
- [61] Del Giudice G, Bianco A, Cennamo A, Santoro G, Bifulco M, Marzo C, Mazzarella G. Lung and Nodal Involvement in Non tuberculous Mycobacterial Disease: PET/CT Role. *Biomed Res Int*. 2015;2015:353202
- [62] Bianco A, Mazzarella G, Rocco D, Gasperi M, Di Marco R, Brunese L. FDG/PET uptake in asymptomatic multilobar Chlamydia pneumoniae pneumonia. *Med Sci Monit*. 2010 Jun;16 (6):CS67-70
- [63] Guarino C, Mazzarella G, De Rosa N, Cesaro C, La Cerra G, Grella E, Perrotta F, Curcio C, Guerra G, Bianco A. Pre-surgical bronchoscopic treatment for typical endobronchial carcinoids. *Int J Surg*. 2016 May 30. pii: S1743-9191 (16)30140-30146
- [64] Fiorelli A, Rizzo A, Messina G, Izzo A, Vicidomini G, Pannone G, Santini M, Di Domenico M. Correlation between matrix metalloproteinase 9 and 18F-2-fluoro-2-deoxyglucose-positron emission tomography as diagnostic markers of lung cancer. *Eur J Cardiothorac Surg*. 2012 Apr;41 (4):852-860
- [65] Fiorelli A, Petrillo M, Vicidomini G, Di Crescenzo VG, Frongillo E, De Felice A, Rotondo A, Santini M. Quantitative assessment of emphysematous parenchyma using multidetector-row computed tomography in patients scheduled for endobronchial treatment with one-way valves†. *Interact Cardiovasc Thorac Surg*. 2014 Aug;19 (2):246-255
- [66] Fiorelli A, Mazzone S, Di Crescenzo VG, Costa G, Del Prete A, Vicidomini G, Mazzone A, Santini M. A simple technique to control placement of Dumon stent in subglottic tracheal stenosis. *Interact Cardiovasc Thorac Surg*. 2014 Mar;18 (3):390-392
- [67] Fiorelli A, Vicidomini G, Mazzella A, Messina G, Milione R, Di Crescenzo VG, Santini M. The influence of body mass index and weight loss on outcome of elderly patients undergoing lung cancer resection. *Thorac Cardiovasc Surg*. 2014 Oct;62 (7):578-587
- [68] Santini M, Fiorelli A, Vicidomini G, Laperuta P. The use of LigaSure for preservation of a previous coronary artery bypass graft by using the left internal thoracic artery in a left upper lobectomy. *J Thorac Cardiovasc Surg*. 2008 Jul;136 (1):222-223

- [69] Santini M, Fiorello A, Di Lieto E, Di Crescenzo VG, D'aniello G, Vicidomini G, Perrone A, Pastore V. Surgical strategies in cervico-mediastinal goiters. *Minerva Chir.* 2006 Jun;61 (3):221-229
- [70] Fiorelli A, Vicidomini G, Messina G, Santini M. Spontaneous expectoration of an obstructive fibrinous tracheal pseudomembrane after tracheal intubation. *Eur J Cardiothorac Surg.* 2011 Jul;40 (1):261-263
- [71] Fiorelli A, Vicidomini G, Milione R, Grassi R, Rotondo A, Santini M. The effects of lung resection on physiological motor activity of the oesophagus. *Eur J Cardiothorac Surg.* 2013 Aug;44 (2):250-6;discussion 257
- [72] Santini M, Fiorello A, Mansi L, Rambaldi PF, Vicidomini G, Busiello L, Messina G, Nargi P. The role of technetium-99m hexakis-2-methoxyisobutyl isonitrile in the detection of neoplastic lung lesions. *Eur J Cardiothorac Surg.* 2009 Feb;35 (2):325-331
- [73] Santini M, Fiorello A, Vicidomini G, Busiello L. Pulmonary hernia secondary to limited access for mitral valve surgery and repaired by video thoracoscopic surgery. *Interact Cardiovasc Thorac Surg.* 2009 Jan;8 (1):111-113
- [74] Corsten MJ, Shamji FM, Odell PF, Frederico JA, Laframboise GG, Reid KR, Vallieres E, Matzinger F. Optimal treatment of descending necrotizing mediastinitis. *Thorax* 1997; 52:702-708
- [75] Deu-Martín M, Saez-Barba M, López Sanz I, AlcarazPeñarrocha R, Romero Vielva L, Solé Montserrat J. Mortality risk factors in descending necrotizing mediastinitis. *Arch Bronconeumol* 2010; 46:182-187
- [76] Mora R, Jankowska B, Catrambone U, Passali GC, Mora F, Leoncini G, Passali FM, Barbieri M. Descending necrotizing mediastinitis: ten years' experience. *Ear Nose Throat J* 2004; 83:774, 776-780
- [77] Makeieff M, Gresillon N, Berthet JP, Garrel R, Crampette L, Marty-Ane C, Guerrier B. Management of descending necrotizing mediastinitis. *Laryngoscope* 2004;114:772-775
- [78] Sancho LM, Minamoto H, Fernandez A, Sennes LU, Jatene FB. Descending necrotizing mediastinitis: a retrospective surgical experience. *Eur J Cardiothorac Surg* 1999; 16:200-205
- [79] Marty-Ané CH, Berthet JP, Alric P, Pegis JD, Rouvière P, Mary H. Management of descending necrotizing mediastinitis: an aggressive treatment for an aggressive disease. *Ann Thorac Surg.* 1999; 68:212-217
- [80] Freeman RK, Vallières E, Verrier ED, Karmy-Jones R, Wood DE. Descending necrotizing mediastinitis: An analysis of the effects of serial surgical debridement on patient mortality. *J Thorac Cardiovasc Surg* 2000; 119:260-267
- [81] Inoue Y, Gika M, Nozawa K, Ikeda Y, Takami I. Optimum drainage method in descending necrotizing mediastinitis. *Interact Cardiovasc Thorac Surg* 2005; 4:189-192
- [82] Iwata T, Sekine Y, Shibuya K, Yasufuku K, Iyoda A, Iizasa T, Saito Y, Fujisawa T. Early open thoracotomy and mediastinopleural irrigation for severe descending necrotizing mediastinitis. *Eur J Cardiothorac Surg.* 2005; 28:384-388
- [83] Chen KC, Chen JS, Kuo SW, Huang PM, Hsu HH, Lee JM, Lee YC. Descending necrotizing mediastinitis: a 10-year surgical experience in a single institution. *J Thorac Cardiovasc Surg.* 2008; 136:191-198
- [84] Lanisnik B, Cizmarevic B. Necrotizing fasciitis of the head and neck: 34 cases of a single institution experience. *Eur Arch Otorhinolaryngol* 2010; 267:415-421
- [85] Karkas A, Chahine K, Schmerber S, Brichon PY, Righini CA. Optimal treatment of cervical necrotizing fasciitis associated with descending necrotizing mediastinitis. *Br J Surg.* 2010; 97:609-615
- [86] Hsu RF, Wu PY, Ho CK. Transcervical drainage for descending necrotizing mediastinitis may be sufficient. *Otolaryngol Head Neck Surg.* 2011; 145:742-747
- [87] Wakahara T, Tanaka Y, Maniwa Y, Nishio W, Yoshimura M. Successful management of descending necrotizing mediastinitis. *Asian Cardiovasc Thorac Ann.* 2011;19:228-231
- [88] Kocher GJ, Hokscho B, Caversaccio M, Wiegand J, Schmid RA. Diffuse descending necrotizing mediastinitis: surgical therapy and outcome in a single-centre series. *Eur J Cardiothorac Surg.* 2012; 42:e66-72
- [89] D'Cunha J, James M, Antonoff MB, Green CA, Andrade RS, Maddaus MA, Beilman GJ. Descending necrotizing mediastinitis: a modified algorithmic approach to define a new standard of care. *Surg Infect (Larchmt)* 2013; 14:525-531
- [90] Guan X, Zhang WJ, Liang X, Liang X, Wang F, Guo X, Zhou Y. Optimal surgical options for descending necrotizing mediastinitis of the anterior mediastinum. *Cell Biochem Biophys.* 2014; 70:109-114
- [91] Dajer-Fadel WL, Ibarra-Pérez C, Sánchez-Velázquez LD, Borrego-Borrego R, Navarro-Reynoso FP, Argüero-Sánchez R. Descending necrotizing mediastinitis below the tracheal carina. *Asian Cardiovasc Thorac Ann.* 2014; 22:176-182
- [92] Palma DM, Giuliano S, Cracchiolo AN, Falcone M, Ceccarelli G, Tetamo R, Venditti M. Clinical features and outcome of patients with descending necrotizing mediastinitis: prospective analysis of 34 cases. *Infection* 2015; 3
- [93] Min HK, Choi YS, Shim YM, Sohn YI, Kim J. Descending necrotizing mediastinitis: a minimally invasive approach using video-assisted thoracoscopic surgery. *Ann Thorac Surg.* 2004; 77:306-310
- [94] Kozuki A, Shinozaki H, Tajima A, Kase K. Successful treatment for descending necrotizing mediastinitis with severe thoracic emphysema using video-assisted thoracoscopic surgery. *Gen Thorac Cardiovasc Surg.* 2010; 58:584-587
- [95] Hirai S, Hamanaka Y, Mitsui N, Isaka M, Mizukami T. Surgical treatment of virulent descending necrotizing mediastinitis. *Ann Thorac Cardiovasc Surg* 2004; 10:34-38
- [96] Iyoda A, Yusa T, Fujisawa T, Mabashi T, Hiroshima K, Ohwada H. Descending necrotizing mediastinitis: report of a case. *Surg Today* 1999; 29:1209-1212
- [97] Malik V, Gadepalli C, Agrawal S, Inkster C, Lobo C. An algorithm for early diagnosis of cervicofacial necrotising fasciitis. *Eur Arch Otorhinolaryngol* 2010; 267:1169-1177
- [98] Sandner A, Börgermann J. Update on necrotizing mediastinitis: causes, approaches to management, and outcomes. *Curr Infect Dis Rep.* 2011; 13:278-286